

## Case Report

Karishma Smart\*, Raymon Durso, Jonathan Morgan and Patrick McNamara

# A potential case of remission of Parkinson's disease

DOI 10.1515/jcim-2016-0019

Received March 14, 2016; accepted May 24, 2016;  
previously published online July 5, 2016

**Abstract:** We present the case of a 78-year-old male who, 16 years ago, was diagnosed with Parkinson's disease (PD) by a neurologist. He initially presented with left-hand tremor, stooped posture, shuffling gait, and frequent falls, which eventually progressed to bilateral motor symptoms after 3 years. Since 2012, his symptoms and signs have almost completely remitted, and he has been off all pharmacotherapy for that time. The accuracy of the initial PD diagnosis is supported by an appropriate clinical presentation, history of positive response to Sinemet, and an abnormal SPECT DaT scan; thus this case suggests the possibility of remission of symptoms in some patients. We propose that the patient's long history of meditation practice may have been one contributing factor of this improvement as meditation has been shown to release dopamine in the striatum.

**Keywords:** meditation, neuroimaging, Parkinson's disease

## Introduction

Parkinson's disease (PD) is an incurable, progressive neurodegenerative disease characterized by loss of dopaminergic neurons in the substantia nigra. The disease pathology tends to initiate unilaterally, resulting in unilateral motor symptoms, which can define a PD diagnosis. Although PD is diagnosed clinically, SPECT DaT

scans are often used to validate a PD diagnosis. These scans are SPECT scans using the DaT radionuclide that binds to the pre-synaptic striatal dopamine reuptake transporter; in a patient with PD, the scan will typically demonstrate asymmetric loss of signal in the striatal regions. In current practice, diagnostic SPECT DaT scans are qualitatively assessed by radiologists, which complicates interpretation of the scan. To reduce interpretative difficulties, SPECT DaT scan images can be coregistered to the patient's MPAGE scan, an anatomical MRI, for enhanced anatomical localization. The voxel intensities can then be used to quantify the asymmetry of DAT binding, indicating asymmetric striatal dopaminergic integrity and thus PD. We performed this and other clinical analyses on the case reported in this paper.

We present here a 78-year-old male patient who was diagnosed with PD over fifteen years ago but whose symptoms have since remitted. The patient was diagnosed clinically with PD by a neurologist, and we provide the quantification of his diagnostic SPECT DaT scan as validation of this diagnosis. Intriguingly, this patient has a long history of involvement in meditative practice. Meditation has been shown to elicit dopaminergic effects, which may counteract the early dopaminergic dysfunction that forms the basis of PD. As such, we posit that decades of potentially dopaminergically protective meditative practice may have contributed, at least in part, to the remission of this patient's parkinsonian symptoms. This also suggests the potential utility of meditation as a non-pharmacological adjunctive intervention for patients with PD. Thus, we offer with this case study the possibility of remission of symptoms in patients with PD and the potential contribution of meditation to such a remission.

## Case presentation

This 78-year-old male initially presented in 2000 with a moderate left-hand tremor noted on finger-to-nose testing, stooped posture, shuffling gait with decreased arm swing bilaterally, and a history of frequent falls, which

**\*Corresponding author: Karishma Smart**, Albert Einstein College of Medicine, Yeshiva University, 1300 Morris Park Avenue, Ullman Building, Rm 223, Bronx, NY 10461, USA,  
E-mail: karishma.l.smart@gmail.com

**Raymon Durso**, Boston University School of Medicine; Boston VA Healthcare System, Jamaica Plain Campus, Department of Neurology, Boston, MA, USA

**Jonathan Morgan**, Boston University, Graduate Division of Religious Studies; Boston VA Healthcare System, Jamaica Plain Campus, Boston, MA, USA

**Patrick McNamara**, Boston University School of Medicine; Boston VA Healthcare System, Jamaica Plain Campus, Boston, MA, USA

he described as “tripping over his feet”. He was referred to a neurologist in the Brockton VA Hospital Neurology Clinic in Brockton, MA and subsequently diagnosed with PD. He was started on Sinemet 10/100 3x daily, which the patient and his neurologist found to ameliorate his symptoms and signs. The patient stated his gait had improved with less shuffling and no falls. His medications upon presentation to the neurologist were lansoprazole, ranitidine, ibuprofen, and aspirin, none of which have documented side effects mimicking or confounding parkinsonian diagnoses. He had no prior drug abuse history or any known history of exposure to pesticides or heavy metals. He led a religious lifestyle, having joined a monastery in 1978 for about a decade. He had taught himself to pray using a technique of “centering prayer” that involved a daily deep meditation of at least 30 min. In 2003, the patient progressed to bilateral motor symptoms, including cogwheeling and bradykinesia in the right upper extremity. This same year, the patient came under the care of one of the authors (RD). From 2003 to 2012, he was seen approximately on a yearly basis. He primarily received Sinemet 25/100 2 tabs 3-4x per day. On different visits, he would have subtle motor findings that varied but occasionally involved mild cogwheeling in either or both upper extremities, rest tremor in either upper limb, and bilateral upper limb bradykinesia. On one visit, he stated that he had worsening symptoms if he forgot a dose of Sinemet, but overall there was no clear development of “on-off”. In 2011, he participated in pharmacologic research that involved on five separate occasions (about 1 week apart) fasting from all medication and food overnight and then receiving a dose of oral carbidopa and 2 hours later 200 mg of stable-isotope labeled levodopa. His fasting UPDRS (Unified Parkinson's disease rating scale) Part III motor score in one study was 22/108, which improved to 14/108 after the study labeled levodopa. In the other four studies, his UPDRS Part III fasting score ranged from 7-9/108 with no improvement after the study carbidopa and stable-isotope labeled levodopa. All studies were scored by the same neurologist. Due to the absence of typical “on-off” phenomena, it was decided to taper and discontinue his Sinemet. He accomplished this in 2012 without any worsening of motor signs, and he has since been off of all forms of pharmacotherapy. The patient never underwent any surgical or other non-pharmacological interventions. His last 2 exams in 2014 were characterized by a gait with stooped posture without any shuffling, festination or difficulty with turns. He had mild bradykinesia in both hands but no cogwheeling or tremor in his limbs.

## Differential diagnosis and imaging

### Vascular parkinsonism

The patient underwent a head CT in 2013, which was negative for vascular parkinsonism and normal pressure hydrocephalus.

### Frontotemporal dementia

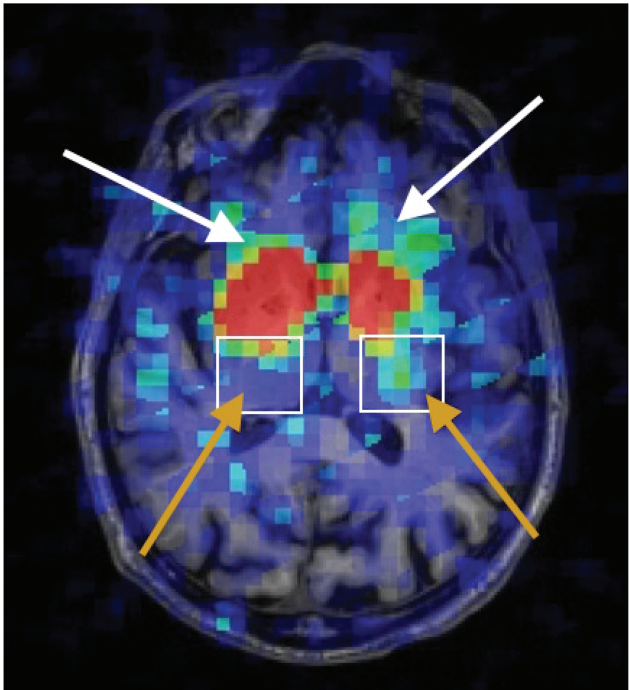
Clinical exam by a neurologist revealed no signs of dementia. The patient's score on the Mini Mental State Examination (MMSE) was 27/30, which falls above the 26/30 age- and education level-adjusted cutoff score for cognitive dysfunction [1], indicating normal cognitive status and thereby ruling out any dementing process such as Frontotemporal Dementia or Lewy Body Dementia.

### Parkinson's disease

The patient underwent a SPECT DaT scan in 2014 to clarify the accuracy of the initial PD diagnosis, which was assessed clinically by a radiologist as abnormal. His only medications at this time were alendronate, terazosin, ASA, and calcium; these medications do not interfere with SPECT DaT results.

### Image quantification

To further investigate the accuracy of the diagnosis, the SPECT scan was coregistered to the patient's Magnetization Prepared Rapid Gradient Echo (MPRAGE), a high resolution anatomical MRI, and quantified using a voxel-based analysis. He underwent the MPRAGE as part of the Cognition & Parkinson's Project. The MPRAGE and SPECT scans were coregistered using the FreeSurfer image processing and analysis software, mitigating the lack of anatomical localization in the SPECT scan due to its poor resolution [2, 3]. The voxel-based quantification involved the voxel intensities of the caudate and putamen. The mean intensity of the pericalcarine gyrus served as an intensity baseline as it has been shown to have little to no dopaminergic activity in SPECT DaT scans [4]. The percentage of voxels exceeding four intensity thresholds in each striatal region was quantified, based off the SPECT quantification method developed by Seibyl et al. [3].



**Figure 1:** SPECT DaT coregistered to MPRAGE. The white arrows are pointing to the left and right caudate. The gold arrows are pointing to the left and right putamen, which is encased in the white box. The scan is in radiological view, so the left hemisphere is on the right side of the scan, and vice versa.

The patient's SPECT scan coregistered to his MPRAGE is shown in Figure 1. The gold arrows show that the tail of the right hemispheric putamen (outlined by the white box) is absent, accounting for the patient's initial left-hand rest tremor. This is supported by the quantification data on the putamen.

The same SPECT scan quantification was performed on another patient diagnosed with PD after presenting with right-hand tremor 2 years before the acquisition of his SPECT DaT scan. Therefore, this patient's caudate and putamen served as "control" regions because they were minimally affected by the disease as of yet. The case patient's right putamen is the more affected hemisphere (MAH), corresponding to the patient's initial left-hand rest tremor. The "control" patient's left putamen is the MAH, corresponding to his initial right-side symptom presentation.

In the case patient, the left caudate had more voxels than the right caudate with intensities that exceeded each pericalcarine threshold. There were no voxels in either the left or the right caudate with intensities that exceeded six times the pericalcarine baseline. Presumably due to the long duration of the case patient's disease, both his left and right caudate had lower intensities than either the left or right "control" caudate.

The case patient's left putamen had more voxels than the right putamen with intensities that exceeded each pericalcarine threshold. Of particular interest, the case patient's right putamen had much lower voxel intensities than the "control" patient's left putamen, corresponding to his longer disease duration. As the putamen is the striatal region associated with the motor symptoms of PD, the lower voxel intensities in the case patient's right putamen (Table 1) correspond to his initial left-hand rest tremor.

**Table 1:** Percent of voxels that exceed four pericalcarine baseline thresholds in the left and right caudate and putamen of the case patient and the left caudate and putamen of the "control" patient.

	Left caudate <sup>a</sup>	Right caudate <sup>b</sup>	"Control" right caudate <sup>c</sup>	"Control" left caudate <sup>d</sup>
4x Baseline	6.81	11.18	65.96	45.18
5x Baseline	1.35	1.66	52.23	22.29
6x Baseline	0	0	22.14	0.11
7x Baseline	0	0	7.52	0
	Left putamen <sup>a</sup> (LAH)	Right putamen <sup>b</sup> (MAH)	"Control" right putamen <sup>c</sup> (LAH)	"Control" left putamen <sup>d</sup> (MAH)
4x Baseline	36.02	26.83	30.26	46.87
5x Baseline	15.32	9.41	16.15	22.42
6x Baseline	1.53	0	6.32	2.24
7x Baseline	0	0	2.33	0

<sup>a</sup>The case patient's left hemispheric mean pericalcarine intensity baseline is 45.49. <sup>b</sup>The case patient's right hemispheric mean pericalcarine intensity baseline is 53.21. <sup>c</sup>The "control" patient's right hemispheric mean pericalcarine intensity baseline is 96.41. <sup>d</sup>The "control" patient's left hemispheric mean pericalcarine intensity baseline is 116.64.

## Discussion

We present an apparent case of remission of symptoms in PD. Parkinson's disease is a progressive, neurodegenerative disease without a cure in which patients tend to progress from unilateral motor symptoms to bilateral motor and neuropsychological symptoms. We define remission in this case report as an amelioration of signs and symptoms of Parkinson disease in the absence of pharmacologic intervention. The patient was clinically diagnosed with PD by a neurologist in the Brockton VA Neurology Clinic 16 years ago. Then, his diagnosis was substantiated by a diagnostic SPECT DaT scan, as per current clinical practice. Finally, the SPECT scan was quantified, and the data attest to the validity of the initial diagnosis. The patient has been off all anti-parkinsonian

pharmacotherapy since 2012 with no clear symptoms or signs of PD. Previously published cases of putative PD remission reveal complicated disease histories and offer compelling evidence for alternative explanations such as drug-induced parkinsonism through a history of drug use [5] and vascular parkinsonism through evidence of ischemic stroke [6]. One group reported that a patient's PD symptoms remitted during a course of immunotherapy for treatment of melanoma, though the symptoms returned after course completion [7].

It is well recognized that PD symptoms and signs can be improved in settings where external or mental stimuli seem to bypass existing motor disability. Some examples of this kinesia paradoxa have been described with visual cueing [8, 9], emotional stress [10], change in motivation [11] and the addition of rhythm through music and dance [12–15]. For some of these actions, the ventral striatum, which processes motivation and emotion, has been proposed as a possible anatomical substrate.

The patient meditates for at least 30 minutes daily using a practice called “centering prayer”, which he learned during his brief time as a postulate in a Franciscan monastery, 37 years ago. In this technique, he focuses his mind on a single religious word to reach a meditative state. He states that he feels less “PD-like” when he meditates so he began to reinvest energy in his meditation practice after his PD onset. There are numerous possibilities that may account for this symptom remission, such as a previously uncharacterized disease progression, an unusually positive response to Levodopa, or the therapeutic contributions of healthy lifestyle habits. One possibility that we would like to bring to the attention of the reader is that the increased intensity of the patient's meditation practice may have contributed to his improvement in parkinsonian signs and symptoms in the absence of medication. One study found that, during Kundalini meditation, putamen activation significantly increase using fMRI [16]. This is a salient attestation of our suggestion as the Hindu yogic practice of Kundalini meditation is based on a similar principle to “centering prayer”, where practitioners maintain attention on a single word to reach a meditative state [16]. Furthermore, the Kundalini study participants had been regular meditators for only four years, whereas this patient has practiced a similar technique for nearly 40 years [16]. This patient's consistent, meditation-induced activation of the putamen for so many decades could have increased its dopaminergic tone, counteracting the DA loss of PD, and thus possibly contributing in part to the remission of his symptoms.

There is growing evidence of the tangible effects that meditation practices exert on the striatum, particularly in the light of recent advances in functional mapping that have revealed corticostriatal modulatory networks, which may mediate cognitive influences, including those produced by meditation, on striatal dopaminergic functioning. Dense modulatory projections from the ventromedial and orbito-prefrontal areas primarily influence the ventral striatum, the rostral caudate nucleus, and the putamen; additional sensorimotor areas project more caudally, primarily to the putamen [17]. Reciprocal connections from limbic sites, including the hippocampus, project back to the basal ganglia and the prefrontal cortex [17]. Thus, these newly discovered corticostriatal networks provide the functional neuroanatomy via which mind-body interventions, such as this patient's meditative practice, can influence the neurologic symptoms of PD.

The influence of these modulatory networks on dopaminergic functioning is further supported by studies specifically investigating the influence of meditation on both striatal dopaminergic functioning, which could then in turn mitigate Parkinson's disease symptoms. For instance, Kjaer et al. demonstrated via [11C]raclopride PET scans that striatal DA increased bilaterally during meditation as compared to a non-meditative rest state [18]. This decrease in binding potential of [11C]raclopride, indicating an increase of endogenous DA, was significant in the ventral striatum [18], suggesting the possibility of “increased dopaminergic tone” during meditative states in these regions [18].

Pagnoni et al. proposed that regular meditation may, over time, help to counteract normal age-related striatal shrinkage and dopaminergic reduction [19]. Their MPAGE study found that meditators did not experience the same extent of age-related decrease in grey matter volume as controls, and this was most apparent in the bilateral putamen [19]. Therefore, consistent meditative practice may offer a benefit to PD patients suffering from striatal DA loss.

Recently, Pickut et al. found that, using MPAGE scans, PD patients who participated in an eight-week mindfulness meditation program exhibited significantly increased striatal grey matter density [20]. The authors pointed out that, as the striatum is a target for dopaminergic therapy in PD, this increase in striatal grey matter density could manifest physically as symptomatic relief [20]. One fMRI study found that cerebral blood flow was higher in the putamen of long-term meditators than in non-meditators [21]. In this study, the long-term meditators had been regularly practicing meditation for at least



fifteen years [21]. As this patient's history of meditative practice is more than twice as long, he may have similar functional brain changes that contributed to his recovery.

## Conclusions

This case has implications for both the effects of meditation practice and the clinical understanding of PD. If the patient's motor symptom remission was indeed due, in part, to his meditation practice, then this case could lend further evidence for the potential benefits of meditation as a non-pharmacological adjunct therapy for PD. We are unable to offer insight as to why the patient presented with PD in the face of such possible benefits of long-term meditation practice; however, intensity of engagement with the practice likely increased after the diagnosis, and he may have benefited from this more intensive practice. Regardless of the role of the patient's meditation, this case demonstrates the possibility of PD symptom remission.

**Author contributions:** All the authors have accepted responsibility for the entire content of this submitted manuscript and approved submission. This work was conducted at Boston VA Healthcare System, Jamaica Plain Campus at 150 S. Huntington Ave., Jamaica Plain, MA, 10461.

**Research funding:** This work was supported by The John Templeton Foundation under Grant #7733510.

**Employment or leadership:** None declared.

**Honorarium:** None declared.

**Competing interests:** The funding organization(s) played no role in the study design; in the collection, analysis, and interpretation of data; in the writing of the report; or in the decision to submit the report for publication.

## References

1. Folstein MF, Folstein SE, McHugh PR. "Mini-mental state": a practical method for grading the cognitive state of patients for the clinician. *J Psychiatr Res* 1975;12:189–98.
2. Marek KL, Seibyl JP, Zoghbi SS, Zea-Ponce Y, Baldwin RM, Fussell B, et al. [123I]beta-CIT/SPECT imaging demonstrates bilateral loss of dopamine transporters in hemi-Parkinson's disease. *Neurology* 1996;46:231–7.
3. Seibyl JP, Marek K, Sheff K, Zoghbi S, Baldwin RM, Charney DS, et al. Iodine-123-b-CIT and Iodine-123-FPCIT SPECT measurement of dopamine transporters in healthy subjects and Parkinson's patients. *J Nucl Med* 1998;39:1500–8.
4. Ravina B, Marek K, Eberly S, Oakes D, Kurlan R, Ascherio A, et al. Dopamine transporter imaging is associated with long-term outcomes in Parkinson's disease. *Mov Disord* 2012;27:1392–7.
5. Tsolaki M, Messini CZ, Siapera M, Fotiadou F, Delaporta D, Karatolias A. Depression, extrapyramidal symptoms, dementia, and an unexpected outcome: a case report. *Cases J* 2010;3:47–51.
6. Lobo R, Fraser A, Kiely P, Boers P. Parkinsonism can be cured. *BMJ Case Reports* 2013;2013:1–3.
7. Shprecher DR, Grossmann KF, Tward JD. Sustained remission of Parkinson disease associated melanoma with immunotherapy. *Parkinsonism Relat Disord* 2014;20:1027–9.
8. Purdon-Martin J. The basal ganglia and posture. London: Pitman Medical Publishing Co. Ltd., 1967.
9. Rahman S, Griffin HJ, Quinn NP, Jahanshahi M. The factors that induce or overcome freezing of gait in Parkinson's disease. *Behav Neurol* 2008;19:127–13.
10. Critchley M. Arteriosclerotic Parkinsonism. *Brain* 1929;52:23–83.
11. Shiner T, Seymour B, Symmonds M, Dayan P, Bhatia KP, Dolan RJ. The effect of motivation on movement: a study of bradykinesia in Parkinson's disease. *PLoS ONE* 2012;7:e47138.
12. Thaut MH, McIntosh GC, Rice RR, Miller RA, Rathbun J, Brault JM. Rhythmic auditory stimulation in gait training for Parkinson's disease Patients. *Movement Disorders* 1996;11:193–200.
13. McIntosh GC, Brown SH, Rice RR, Thaut MH. Rhythmic auditory-motor facilitation of gait patterns in patient's with Parkinson's disease. *J Neurol Neurosurg Psychiatry* 1997;62:22–6.
14. Sharp K, Hewitt J. Dance as an intervention for people with Parkinson's disease: a systematic review and meta-analysis. *Neurosci Biobehav Rev* 2014;47:445–56.
15. Mueller K, Fritz T, Mildner T, Richter M, Schulze K, Lepsien J, et al. Investigating the dynamics of the brain response to music: a central role of the ventral striatum/nucleus accumbens. *Neuroimage* 2015;116:68–79.
16. Lazar SW, Bush G, Gollub RL, Fricchione GL, Khalsa G, Benson H. Functional brain mapping of the relaxation response and meditation. *Neuroreport* 2010;11:1581–5.
17. Haber SN. Corticostriatal circuitry. *Dialogues Clin Neurosci* 2016;18:7–21.
18. Kjaer TW, Bertelsen C, Piccini P, Brooks D, Alving J, Lou HC. Increased dopamine tone during meditation-induced change of consciousness. *Brain Res Cogn Brain Res* 2002;13:255–9.
19. Pagnoni G, Cekic M. Age effects on gray matter volume and attentional performance in Zen meditation. *Neurobiol Aging* 2007;28:1623–7.
20. Pickut BA, Hecke WV, Kerckhofs E, Marien P, Vanneste S, Cras P, et al. Mindfulness based intervention in Parkinson's disease leads to structural brain changes on MRI: A randomized controlled longitudinal trial. *Clin Neurol Neurosurg* 2013;115:2419–25.
21. Newberg AB, Wintering N, Waldman MR, Amen D, Khalsa DS, Alavi A. Cerebral blood flow differences between long-term meditators and non-meditators. *Conscious Cogn* 2010;19:899–905.